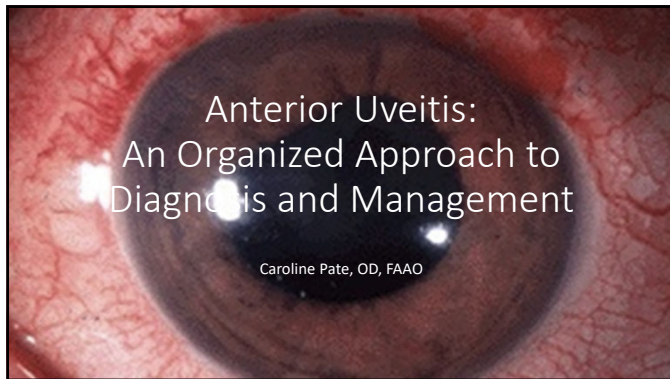

1

No financial disclosures

Acknowledgments: Dr. Tammy Than

2

Why Anterior Uveitis?

- Because its not uncommon
- Because these patients will show up as walk-ins or add-ons
- Hesitancy to manage/quick to refer
- Anterior uveitis – because covering all of uveitis would take more than 2 hrs
 - Uveitis involving the posterior segment should be managed by a retinal specialist

3

Classification: Anatomical

Anterior

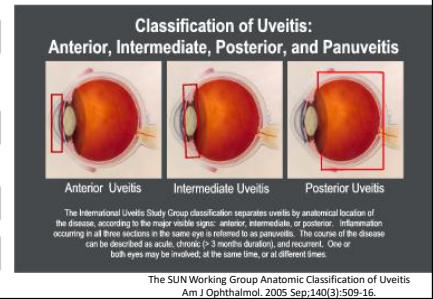
- Iritis, cyclitis, iridocyclitis

Intermediate

- Pars Planitis

Posterior

Panuveitis



4

Epidemiology

- Uveitis – most common form of ocular inflammation
- Anterior uveitis accounts for ~90% of all uveitis
- Most commonly affects working age adults (20-59)
 - M=F
 - Special considerations in young & elderly
- Incidence varies greatly by geographic location

Foster, 2016; Dunn, 2015

5

Epidemiology

- 3rd leading cause of blindness in the world
 - Accounts for 10-15% of all legal blindness (30,000 new cases annually) in US
- In the US, > \$240 million spent annually on the treatment of uveitis and its complications

Foster, 2016; Dunn, 2015; Bajwa, 2015; Hunter, 2011

6

Pathophysiology

- Exact pathophysiology is not known
- Intraocular space is normally free of inflammatory cells because the BAB (anterior) and BRB (posterior) do their job
- Inflammation → tissue changes → vasodilation and ↑ vasopermeability

7

Pathophysiology

- Extravasation
 - > WBC (cells)
 - > Protein (flare)
 - > Larger MW proteins (fibrinogen → fibrin)
 - Keratic Precipitates
 - Synechia
 - Anterior
 - Posterior

8

Pathophysiology

- Retinal Changes
 - Cystoid macular edema (CME)
 - Exudative retinal detachment (rare)

9

What causes vision loss in uveitis?

- Band keratopathy
- Cataract
- Macular Edema*
- Epiretinal membrane*
- CNVM*
- Retinal vasculitis
- Retinal detachment
- Glaucoma
- Optic neuropathy

Series from Moorfields Eye Hospital – at 10-yr f/u

- 80% had VA > 20/50
- 90% had VA > 20/200
- CME, Macular scarring*, ERM = 79% of vision loss <20/50
- Macular scarring, CME, RD, = 71% of vision loss <20/200

Tomkins-Netzer, Ophthalm, 2014

10

What causes uveitis?

- Idiopathic → “Undifferentiated”
 - 35-40% (Foster, 2016)
 - 40-50% (Colmant, 2018)
- Trauma
- Post-operative
- Associated with ocular disease
- Associated with systemic disease
- Drug induced

11

Principles of Uveitis Diagnosis

- Accurate diagnosis
- Accurate description/classification
- Understand the epidemiology and clinical characteristics of uveitic entities
- Targeted history and work up

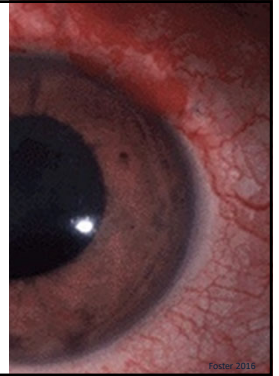
12

Anterior Uveitis: Diagnosis and Description

13

Clinical Presentation

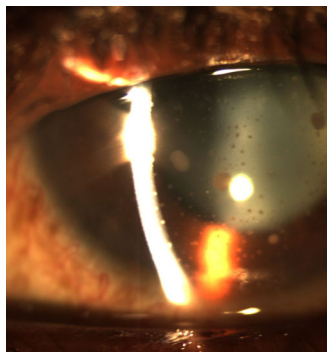
- Symptoms
- Can be asymptomatic!
 - JIA (Juvenile Idiopathic Arthritis)
 - Fuch's
- Conjunctiva
- Pupils
- IOP




14

Clinical Examination - Cornea

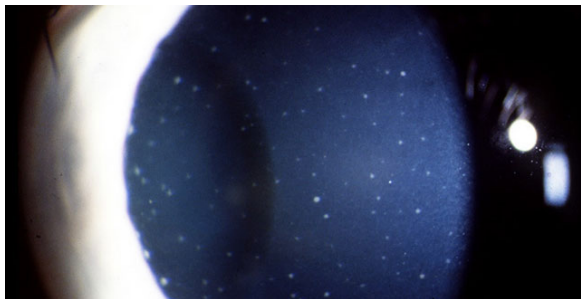
- Keratic Precipitates
- Collection of inflammatory cells
- **Non-granulomatous**: fine, white deposits: collections of lymphocytes, plasma cells, and pigment
- **Granulomatous**: large, "greasy" appearance, "mutton-fat": collections of lymphocytes, plasma cells, and giant cells



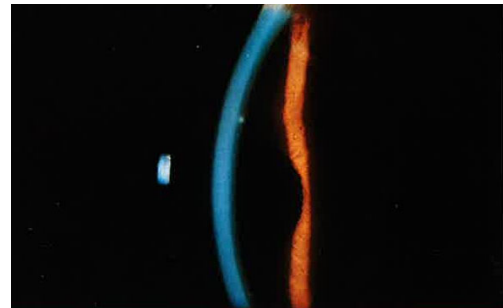
15



16



17



18

Do KPs actually help us????

“MFKPs are typically associated with granulomatous inflammation”

Syphilis		Sarcoidosis		Tuberculosis	
Keratic precipitates (%)		Keratic precipitates, %		Keratic precipitates (%)	
None	45	None	52	None	88
Fine	33	Fine	18	Fine	5
Round	11	Round	6	Round	3
Stellate	2	Stellate	0	Stellate	0
Mutton fat	9	Mutton-fat	23	Mutton fat	4

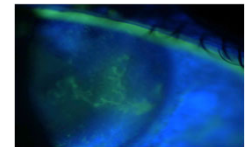
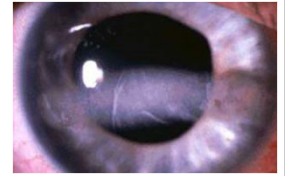
Spondyloarthritis/HLA-B27		Fuch's	
Keratic precipitates,		Keratic precipitates (%)	
None	0	None	1
Fine	41	Fine	25
Round	54	Round	7
Stellate	5	Stellate	68
Mutton-fat	0	Mutton Fat	0
Other	0	Other	0

SUN working group, Am J Ophthalmol, 2021;228:65-280

19

Clinical Examination - Cornea

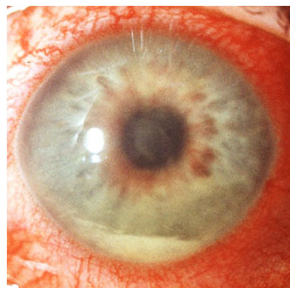
- Edema
- Band keratopathy
 - Can be seen in chronic conditions
 - JIA
- Consider Herpes
 - Check for cornea hypoesthesia
 - Dendritic involvement ?



20

Clinical Examination – Anterior Chamber

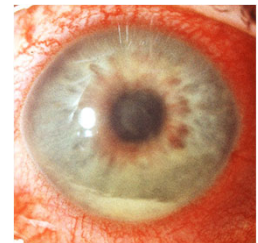
- **Cells:** WBC/Leukocytes
- **Flare:** Protein = from vasodilation and ↑ permeability of inflamed blood vessels
 - Does not = active inflammation
- **Hypopyon:** layering of WBC



21

Hypopyon

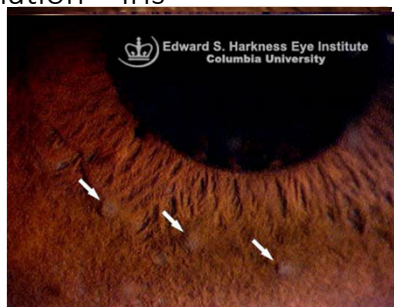
- Differential diagnosis:
 - HLA-B27 anterior uveitis
 - Bechet's
 - Infectious
 - Endophthalmitis (post-surgical or endogenous)
 - Associated with corneal ulcer
 - Drug related (rifabutin)
 - Pseudo-hypopyon (malignant cells, lens induced, steroids)



22

Clinical examination – Iris

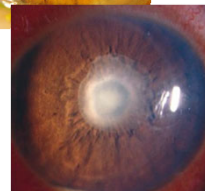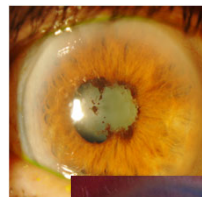
- Examine for synechia
- Any atrophy?
- Inflammatory nodules
 - Associated with sarcoid, TB, syphilis
 - Koeppe
 - Busacca
 - Berlin



24

Posterior synechiae

- Sometimes this is all you get after dilation
- Complications
 - Poor view of posterior pole
 - Decreased vision
 - Secondary angle closure from iris bombe
 - Complicates cataract surgery
- “Occlusio pupillae”- fibrin growth over entire pupil



25

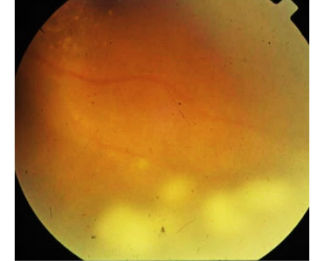
Clinical examination - Lens

- Phakic patient
 - Inspect for signs of trauma
 - Vossius ring
 - Rosette cataract
 - May develop cataract secondary to chronic uveitis
- Pseudophakic patient
 - Residual lens material?

26

Clinical findings - Vitreous

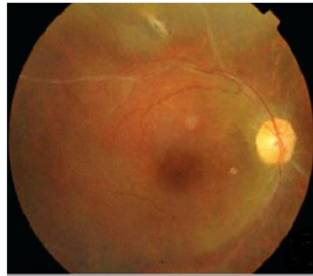
- Haze
- Cells (spillover from A/C)
- Snowballs
 - Collections of inflammatory cells
- Snowbanking
 - Inflammatory exudates over pars plana



27

Clinical findings – Retina/Choroid

- CME
- Retinal vasculitis
- Retinal ischemia/hemorrhage
- Retinal/choroidal lesions
- Retinal/choroidal NV
- Retinal detachment



28

If this is a lecture about anterior uveitis, why even mention posterior segment findings?

- Because uveitis ALWAYS involves the posterior pole until proven otherwise!
- So when **should** you dilate a patient who presents with a uveitis?
 - Always
 - At all times
 - 100% of the time
 - All of the above


29

Classification

30

Classification

- Based on Standardization of Uveitis Nomenclature for Reporting Clinical Data. Results of the First International Workshop.
- Characterized uveitis by:
 - Anatomic type/location
 - Onset/duration and clinical course
- Standardized evaluation



31

SUN Classification – Important Descriptors

Onset

- Sudden
- Insidious

Duration

- Limited
 - ≤3 months duration
- Persistent
 - >3 months duration

Course

- **Acute**
 - Episode characterized by sudden onset and limited duration
- **Recurrent**
 - Repeated episodes separated by periods of inactivity without treatment ≥3 months in duration
- **Chronic**
 - Persistent uveitis with relapse in <3 months after discontinuing treatment

32

Anatomical Classification

Type	Primary Site of Inflammation ¹	Includes
Anterior uveitis	Anterior chamber	Iritis Iridocyclitis Anterior cyclitis
Intermediate uveitis	Vitreous	Pars planitis Posterior cyclitis Hyalitis
Posterior uveitis	Retina or choroid	Focal, multifocal, or diffuse choroiditis Chorioretinitis Retinochoroiditis Retinitis Neuroretinitis
Panuveitis	Anterior chamber, vitreous, and retina or choroid	

SUN Working Group, AJO 2001

33

SUN Grading Scheme for Cells

• 1 x 1 mm beam




Grade	Cells in Field
0	<1
0.5+ (trace)	1 – 5
1+	6 – 15
2+	16 – 25
3+	26 – 50
4+	> 50

34

SUN Grading Scheme for Flare

• 1 x 1 mm beam



Grade	Description
0	optically empty (compare bilaterally)
1+	Faint haze
2+	Moderate (Iris and lens detail clear)
3+	Marked (Iris and lens details hazy)
4+	Intense (fibrin; coagulated aqueous)

35

Treatment of Anterior Uveitis

36

Treatment of Anterior Uveitis - GOALS

- Preserve vision
 - Relieve pain
 - Reduce ocular inflammation
 - Prevent sequelae
 - Target the cause
- SUCCESS = induction of durable, corticosteroid-free remission

37

Agents utilized

- Cycloplegics (and mydriatics)
- Topical corticosteroids
- Oral corticosteroids
- Periocular steroids
- Immunomodulators

38

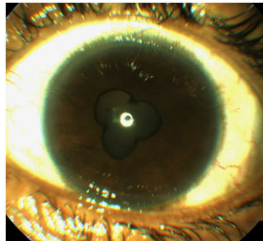
Cycloplegics

- **Immobilize inflamed iris**
- **Prevent posterior synechia**
- **Stabilize the leaky blood-aqueous barrier**
- Options:
 - Cyclopentolate – not preferred due to short duration of action
 - Homatropine – pharmacy availability issues
 - Atropine – strongest cycloplegic

39

Mydriatics

- 10% phenylephrine can be useful in breaking synechia in-office
- In office concoction – soak cotton pledget in:
 - 10% phenylephrine
 - 1% atropine
 - 1% cyclopentolate



40

Topical Corticosteroids

- **Better to overtreat than undertreat** early on in the disease process
- Stabilize cell membranes
- Inhibit release of lysozyme by granulocytes
- Suppress circulation of lymphocytes

41

HIT IT HARD AND TAPER SLOW

Prednisolone acetate
1%

Difluprednate 0.05%

Need at least a 2 grade
reduction in activity to
begin tapering
e.g. improvement
from 3+ cell to 1+
cell

Weaker steroids –
possible use as a taper

42

Corneal Penetration and Anti-inflammatory Efficacy

Epithelium Intact		Epithelium Absent	
Pred Acetate 1%:	51%	Pred Acetate 1%:	53%
Pred Phosphate 1%:	28%	Pred Phosphate 1%:	53%

Musson, D G (1991). "Comparative corneal penetration of prednisolone sodium phosphate and prednisolone acetate in NZW rabbits.". *Journal of ocular pharmacology*(8756-3320), 7 (2), p. 175

43

Steroid dosing based on severity (prednisolone acetate)

- Mild
 - Every 4 hours
- Moderate
 - Every 2 hours
- Severe
 - Every ½ - 1 hour (or even more frequently)
 - Every 2-3 hours at night

44

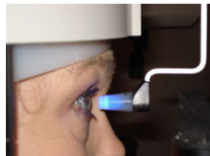
Ophthalmic steroid ointment

- Fluorometholone ophthalmic ointment 0.1%
- Loteprednol ophthalmic ointment 0.5%

45

Ocular Side Effects of Treatment

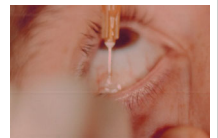
- Iatrogenic (Steroid) OHT
 - Interference with phagocytosis in Schlemm's canal
 - Increased accumulation of glycosaminoglycans (GAGS) in TM
- Management...



46

Periocular Steroids

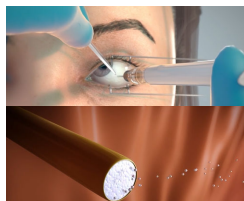
- Subconjunctival or sub-Tenon's
- Triamcinolone or methylprednisolone
- Recalcitrant anterior uveitis, intermediate uveitis, posterior uveitis
- r/o "steroid responder"
- Do not administer if etiology is infectious



47

Uveitis Approved Steroid Implants

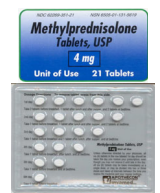- All approved for noninfectious uveitis affecting posterior segment of the eye
- Retisert®-0.59mg fluocinolone acetonide
- Ozurdex™-0.70mg Dexamethasone
- Yutiq™- 0.18mg fluocinolone acetonide



48

Oral Steroids

- Posterior, pan, or recalcitrant uveitis
- Must rule out infections (e.g., tuberculosis)
- Side effects
- Prophylactic acid reducer
- Prednisone
 - Start high and taper quickly
 - 1-2 mg/kg/day (~60-100 mg/day)
- Medrol Dosepak ?



50

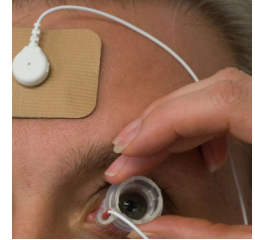
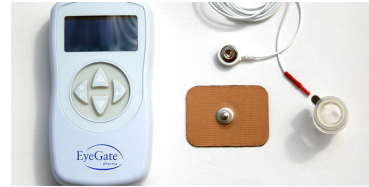Immunomodulators

- Antimetabolites
 - Methotrexate, Azathioprine
- Inhibitors of T-lymphocytes Signaling
 - Cyclosporine, Tacrolimus
- Alkylating Agents
 - Cyclophosphamide, Chlorambucil
- Biologics
 - Adalimumab – FDA approval for uveitis
 - Infliximab – off label

51

What's the future?

- EGP-437 Eyegate II Delivery System
- Trans-scleral iontophoresis



52

Overall Management

- Re-evaluate 1-7 days
- Cycloplegic usually stopped before steroid
 - No need to taper
- Continue topical steroid until cells are gone
 - Taper
- Evaluate patient during taper and post-taper
 - IOP
- What's the etiology?

54

Targeted history and diagnostic workup

55

Why work up a uveitis patient?

- To determine if they have an infectious etiology that can be treated
- To diagnose an underlying systemic disorder that could be managed and therefore improve their quality of life
- *Finding an associated disorder is NOT curative!*

56

Infectious Diseases	<ul style="list-style-type: none"> • Bacterial: syphilis, tuberculosis, Lyme disease, cat-scratch disease, rickettsiosis, leptospirosis, brucellosis, Whipple's disease • Parasitic: toxoplasmosis, toxocariasis, Onchocerciasis • Viral: herpes virus, CMV, HTLV-1 • Fungal: candidiasis, histoplasmosis 	Ocular entities	<ul style="list-style-type: none"> • Posner-Schlossman syndrome • Fuchs uveitis syndrome • Sympathetic ophthalmia • Phacoantigenic uveitis • Serpiginous choroiditis • Birdshot chorioretinopathy • Multifocal choroiditis • Placoid epitheliopathy • Pars planitis
Systemic Inflammatory Diseases	<ul style="list-style-type: none"> • HLA-B27-associated uveitis • Sarcoidosis • Behcet's disease • Vogt-Koyanagi-Harada disease • Juvenile idiopathic arthritis • Systemic lupus erythematosus • Multiple sclerosis • Tubulointerstitial nephritis and uveitis (TINU syndrome) • Chronic inflammatory bowel disease 	Drug-induced	<ul style="list-style-type: none"> • Rifabutin • Bisphosphonates • Fluoroquinolones
		Masqueraders	<ul style="list-style-type: none"> • Trauma, intraocular FB • Tumors (oculocerebral lymphoma, melanoma, retinoblastoma, metastases)

Adapted from Seva 2015

57

Anatomic Location	Infectious	Systemic Disease	No Systemic Disease
Anterior uveitis	<ul style="list-style-type: none"> • CMV • HSV • Varicella zoster • Syphilis • TB • Lyme 	<ul style="list-style-type: none"> • HLA-B27 assoc • Juvenile idiopathic arthritis-assoc • Behcet disease • Sarcoidosis • MS 	<ul style="list-style-type: none"> • Fuchs uveitis syndrome • Post-traumatic
Intermediate	<ul style="list-style-type: none"> • Syphilis • Lyme disease 	<ul style="list-style-type: none"> • Multiple sclerosis • Sarcoidosis 	<ul style="list-style-type: none"> • Pars planitis
Posterior	<ul style="list-style-type: none"> • Toxoplasmic retinitis • CMV retinitis • Acute retinal necrosis • Progressive outer retinal necrosis • Diffuse unilateral subacute neuroretinitis • Syphilis • Lyme disease 	<ul style="list-style-type: none"> • Sarcoidosis 	<ul style="list-style-type: none"> • Serpiginous choroiditis • Acute posterior multifocal placoid pigment epitheliopathy • Multiple evanescent white dot • Birdshot chorioretinitis • Diffuse unilateral subacute neuroretinitis • Multifocal choroiditis with panuveitis • Punctate inner choroiditis • Relentless placoid choroiditis ("ampiginous")
Panuveitis	<ul style="list-style-type: none"> • Syphilis disease • Lyme disease • TB • ARN 	<ul style="list-style-type: none"> • Behcet disease • Vogt-Koyanagi-Harada • Sarcoidosis 	<ul style="list-style-type: none"> • Sympathetic ophthalmia

Adapted from Jibin AJO 2011

58

Uveitis "Top 10" – Duane's Ophthalmology Most Commonly Encountered Causes

1. Traumatic
2. Post-surgical
3. Anterior Idiopathic/Undifferentiated
4. HLA-B27 associated uveitis
5. JIA associated uveitis
6. Fuch's uveitis syndrome
7. Posner-Schlossman syndrome
8. Herpetic anterior uveitis
9. Pars Planitis
10. TB/Sarcoid/Syphilis

Adapted from Duane's Ophthalmology

59

Consider the presentation....

Acute, unilateral (or bilateral) non-granulomatous AU

Chronic, bilateral (or unilateral), non-granulomatous AU

Granulomatous AU (unilateral or bilateral)

60

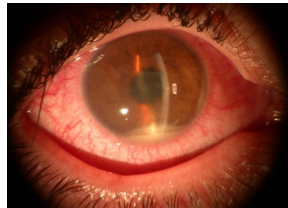
Acute Non-Granulomatous Anterior Uveitis

- Idiopathic (most common)
- HLA-B27
 - Ankylosing spondylitis
 - Reactive arthritis
 - Inflammatory Bowel Dz
 - Psoriatic arthritis
- Behçet's disease
- Trauma
- Infections
 - HZV, HSV, CMV
 - Post operative endophthalmitis
 - Lyme Dz
 - Syphilis
- Lens Induced
- UGH (uveitis-glaucoma-hyphema)

61

Case – 30 yo WM

- Similar episode 2 years ago in other eye
- No recent surgery or trauma
- ROS: + lower back pain worse in am
- Social hx: no recent tick bites, foreign travel, no drug use
- VA: OD20/100 OS: 20/20
- IOP: 11/15
- Pupils: OD poorly reactive, OS normal
- DFE: Hazy view OD but normal b-scan, OS normal



62

Autoimmune/inflammatory disorders

63

Seronegative spondyloarthropathies (SAs)

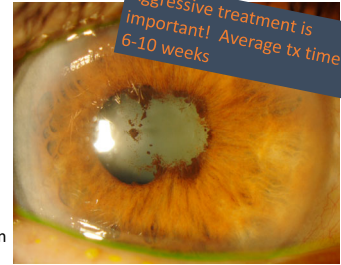- Group of inflammatory rheumatic diseases that cause arthritis of the spine (Seronegative = negative RF)
 - **Ankylosing Spondylitis**
 - **Reactive arthritis**
 - **IBD (ulcerative colitis; Crohn disease)**
 - **Psoriatic arthritis**
- Hereditary; major gene that causes it is **HLA-B27**
- Can affect the joints of the arms and legs (e.g. hips and shoulders) as well as involve the skin, intestines and eyes
- Frequently undiagnosed; mean time to dx after onset of symptoms is 6 years

Haxton, 2015; <https://www.rheumatology.org>

64

SA/HLA-B27 associated uveitis

- Accounts for ~20% of all uveitis
- Acute, rapid onset of unilateral pain and intense photophobia
- Non-granulomatous
- Moderate-severe A/C reaction (3-4+ cells, plasmoid aqueous, fibrin, +/-hypopyon)
- Posterior synechiae common



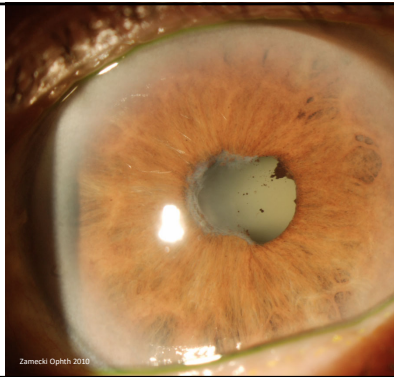
Aggressive treatment is important! Average tx time = 6-10 weeks

Zamecki Ophth 2010; Chang Surv 2005

65

SA/HLA-B27 associated uveitis

- Of **recurrent, acute, unilateral alternating anterior uveitis**: 80% will have a SA or be HLA-B27 positive
- Of patients with uveitis and (+) HLA-B27, 60-76% will have an associated SA
 - And about half of these SAs will have been undiagnosed or misdiagnosed

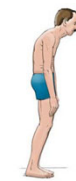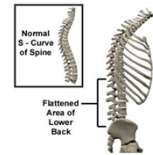


Zamecki Ophth 2010

66

Ankylosing Spondylitis

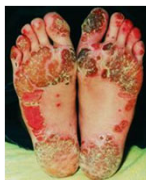- Aggressive inflammatory arthropathy
- Onset usually in 20s
- Rare in AA
- M>F (females less severe)
- **Lower back pain**
 - Worse after inactivity
- "Bamboo spine"
- 25% have anterior uveitis
 - May present years before skeletal signs
 - High rate of recurrence
 - Can alternate between two eyes
 - Resolution between attacks



67

Reactive Arthritis

- Formerly known as Reiter's syndrome
- "Can't see, can't pee, can't climb a tree"
 - Conjunctivitis/Uveitis
 - Urethritis
 - Arthritis – lower joints affected
 - Only 1/3 have all 3
- Dermal skin lesions
- More common in men
- 75-90% HLA-B27+
- Often follows genitourinary infection



68

Other SA/HLA-B27 conditions

- Inflammatory Bowel Disease
 - Ulcerative Colitis
 - Crohn's disease
 - Diarrhea, bloody stools, cramping
 - GI referral
- Psoriatic arthritis
 - Arthritis of upper extremities
 - Characteristic skin lesions – red patches with silvery scales

69

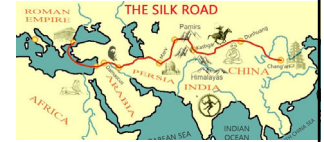
Rheumatoid arthritis

- Uveitis misconception
- Psoriatic, reactive and JIA true etiologies
- Common cause of Scleritis/Episcleritis

70

Behçet's disease

- Most prevalent along the ancient Silk Road that extends from the eastern Mediterranean to Japan
- Most common in **Middle East, Turkey** (42/10,000) and **Japan** (1/10,000)
- In Saudi Arabia, one of the most common causes of uveitis

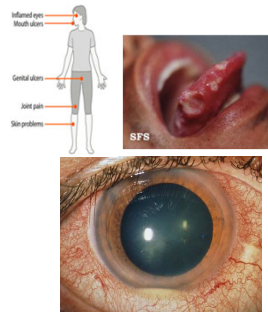


KACMAZ, AJO 2008

71

Behçet's disease

- Chronic multisystem inflammatory disease of unknown etiology
- Characterized by recurrent episodes of:
 - Uveitis with hypopyon
 - Oral ulcers
 - Genital ulcers
 - Retinal vasculitis
 - Skin lesions



Reiff, 2013; KACMAZ, AJO 2008

72

Behçet's disease

- Diagnosis based on specific clinical findings, as there is no specific lab test
- Associated with HLA-B51
- Males > Females
 - Although reverse may be true in US and Western Europe
- Usually bilateral (80%)
- In 20% of cases, ocular involvement may be the initial manifestation
 - Panuveitis most common (up to 89% - Arevalo 2015)
 - Posterior seg involved in ~ 70% of patients
- Acute inflammation of retinal arteries and veins

Reiff, 2013; KACMAZ, AJO 2008

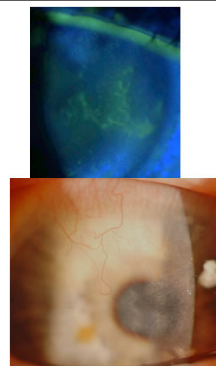
73

Infectious disorders

74

Herpetic Uveitis

- HSV
 - h/o unilateral red eye
 - Blur, photophobia, pain, redness
 - May have active corneal disease
 - Use Rose Bengal stain!
 - Reduced corneal sensitivity
- Usually secondary to keratitis but *may present without corneal involvement*
- HSV – uveitis usually with stromal or disciform keratitis



75

HSV Keratouveitis

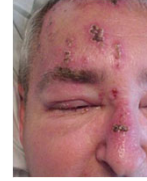– how to stay out of trouble

- ALWAYS look at the cornea – in most **non-herpetic** uveitis, the anterior part of the cornea is NOT involved and there is NO corneal edema
- Clues to consider HSV:
 - Multiple episodes in same eye
 - High/asymmetric IOP
 - Fine, stellate KPs
- Consider dendrite masqueraders: e.g. epithelial regeneration line after a corneal abrasion
- If cornea is compromised/when in doubt, do NOT use a steroid

76

Herpes Zoster

- Most common > age 50 OR immunosuppressed
- In one population-based study, **2.5%** of all pts with HZ had ocular involvement
- ~1/3 of cases involving the ocular dermatome had ocular involvement

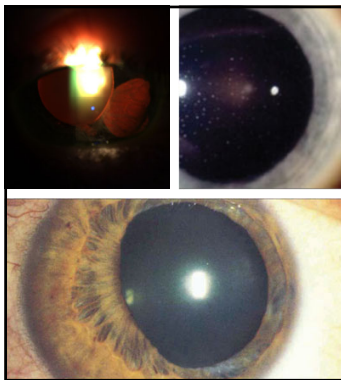


Ocular findings:

- Keratitis: 76%
- Iritis/uveitis: 47%
- Conjunctivitis: 35%
- Severe eye pain: 14%
- Increased IOP: 12%

Yawn et al Mayo Clin Proc 2013

77



HZ uveitis

- Occurs in ~ 47% of pts with HZO
- Usually starts 1-3 weeks after rash
- Unilateral; usually mild and transient
- Increased IOP
- Diffuse small KP
- Iris atrophy (sectoral or diffuse) and irregular pupil

78

Chronic, Nongranulomatous Anterior Uveitis

- Juvenile Idiopathic Arthritis (JIA)
- Fuchs' Uveitis Syndrome
- Autoimmune disease

79

Juvenile Idiopathic Arthritis (JIA)

- Formerly known as JRA
- **80% of pediatric uveitis cases are associated with JIA**
 - Most prevalent systemic disorder in children with uveitis
- Children < 16 yrs; F>M
- Chronic **bilateral** anterior uveitis – usually **ASYMPTOMATIC**
 - Slow, chronic onset
- Fine or no KP with posterior synechiae
- Band keratopathy

Ayuso, Surv Ophthalmol 2014

80

Juvenile Idiopathic Arthritis (JIA)

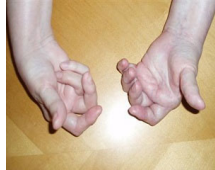- Group of clinically distinct arthritic disorders characterized by:
 - Asymmetric arthritis
 - Early age of onset
 - Female predilection
 - (+) ANA
- Multifactorial autoimmune disorder to which patients are genetically predisposed and may be influenced by environmental factors and infections

Ayuso, Surv Ophthalmol 2014

81

Juvenile Idiopathic Arthritis (JIA)

- Oligoarticular JIA
 - 50%
 - ≤ 4 joints
 - F>M
 - **30% develop AU**
- Polyarticular JIA
 - 20%
 - ≥ 5 joints
 - May have uveitis
- Systemic JIA
 - 30%
 - Uveitis is *extremely rare*



82

Other childhood uveitis

TINU (tubulointerstitial nephritis and uveitis syndrome)

- Rare; 1st reported 1975
- Mean age 14-15, 3x F>M
- Presents with ant uveitis, later followed by acute interstitial nephritis
- Responds well to corticosteroid therapy
- Urinalysis: + Beta-2 microglobulin

Pars Planitis

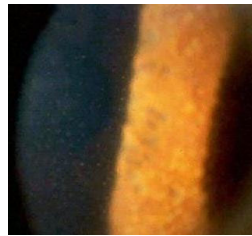- Typically children and adolescents; M > F
- Usually bilateral
- Subset of idiopathic intermediate uveitis, with snow banking or snowball formation at the pars plana
- Rarely associated with a systemic disease

Reiff 2013

83

Fuch's uveitis syndrome (FUS)

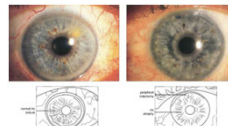
- Unilateral (90%), recurrent low grade uveitis, little injection or pain
- Iris heterochromia or atrophy
- NO posterior synechiae
- **Fine/stellate diffuse KP over entire endothelium**



84

Fuchs' uveitis syndrome (FUS)

- **Glaucoma, cataract**
- Vitreous opacities, iris nodules, abnormal vessels in angle, chorioretinal scars
- Does not tend to respond well to topical steroids!
- Exact etiology unknown
 - Likely associated with rubella virus
 - Quentin and Reiber (2004) found evidence of intraocular production of antibodies against rubella virus in all 52 of their FUS pts
 - Since vaccination program against rubella started in US, sharp decline in FUS cases



Cunningham 2005, Rothova 2007

85

Granulomatous Anterior Uveitis (unilateral or bilateral)

- **RARELY EVER IDIOPATHIC**
- Most common causes:
 - Sarcoid
 - Syphilis
 - TB

86

Sarcoidosis

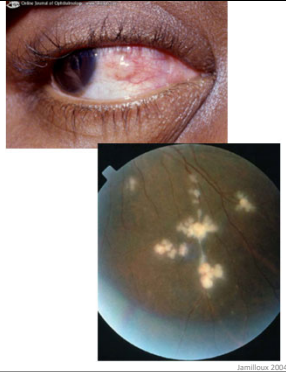
- Multisystem granulomatous inflammatory autoimmune disease of unknown etiology
 - Young, AA females in US
 - #2 systemic etiology of uveitis in U.S.
- Lungs (95%), lymphatics, eyes (25-60%), skin (25%), nervous system, cardiac, liver, laryngeal

Jamilloux 2004, Januzzi NEJM 2007

87

Ocular Sarcoid

- Up to 25–60% of patients have ocular involvement
 - Nodules/Ant Seg Granulomas
 - Chronic dacryoadenitis
 - Uveitis
 - Posterior Segment
 - Candle wax drippings
 - Vitritis
 - CME



88

Ocular Sarcoid Uveitis

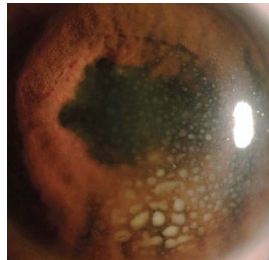
- Can produce any type of uveitis
 - Ant uveitis: 41–75%
 - Intermediate: 6–10%
 - Posterior: 28%
 - Panuveitis: 9–30%

Jamilloux 2004

89

Ocular sarcoid - Anterior segment

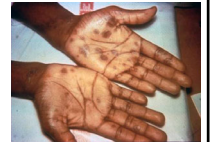- Bilateral
- Granulomatous
 - Large mutton-fat KP's
- Anterior and posterior synechiae
- Nodules
 - Koeppel
 - Busacca
 - Berlin



90

Syphilis

- A chronic, multistage sexually transmitted disease caused by the spirochete *Treponema pallidum*
 - Primary: sores at original site of infection "chancere"
 - Secondary: skin rash, swollen lymph nodes, fever
 - Latent: no symptoms
 - Tertiary: neurologic, sometimes cardiovascular involvement
- **Ocular syphilis can occur during any stage**
- Standard uveitis treatment + Penicillin G



Mandell, Douglas, and Bennett's Principles and Practice of Infectious Diseases, 2015

91

Ocular Syphilis

- Can involve almost any eye structure
 - Posterior uveitis and panuveitis most common
 - Anterior uveitis
 - Optic neuropathy
 - Retinal vasculitis
 - Interstitial keratitis
- CDC reports rise in rate of cases every year since 2000
 - Majority in HIV+ MSM
- Cases of ocular syphilis should be reported to state/local health department within 24 hours of dx

www.cdc.gov/std/syphilis/stats.htm

92

Tuberculosis

- Infectious disease caused by *Mycobacterium tuberculosis*
 - ¼ of the world's population is infected with TB
 - Rare in US
 - Six countries account for 60% of the total cases: India, Indonesia, China, Nigeria, Pakistan and South Africa

www.cdc.gov/tuberculosis

95

Tuberculosis

Latent TB Infection

- TB bacteria live in the body without making the person sick
- No symptoms; patients don't feel sick
- Can't spread TB
- May develop active TB disease if untreated
- Usually have a positive PPD

TB Disease

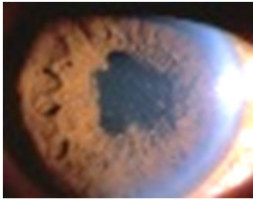
- Feel sick: cough, weakness or fatigue weight loss, chills, fever, sweating at night
- Can spread to others
- Chest X-ray/Sputum culture to Dx
- Requires treatment to prevent spread

<https://www.cdc.gov/tb> <http://www.who.int/mediacentre/factsheets/fs104/en/>

96

Ocular Tuberculosis

- Most common: posterior uveitis, granulomatous anterior uveitis, panuveitis, and intermediate uveitis
- Other signs (most significant in endemic areas)
 - Phlyctenular keratoconjunctivitis
 - Retinal perivasculitis
 - Multifocal serpiginoid choroiditis
 - Choroidal or optic disc granuloma



Figueira 2016; Ang BIO 2016

97

Ocular Entities

98

Posner-Schlossman Syndrome Glaucomatocyclitic crisis

- Mild unilateral non-granulomatous anterior uveitis with **markedly elevated IOP**
 - recurrences may affect either eye
 - at risk for OAG
- Minimal symptoms, open angles
 - Mild hyperemia
 - Mild corneal edema
 - Sentinel KPs
 - May also have diffuse iris atrophy
- **Unlike Fuchs, responds well to steroids**
 - Cycloplegia often not necessary
 - **Avoid PG for IOP control**

Magno et al Surv Ophthalmol 2022

99

Drug-Induced uveitis

- Rare – incidence <1%
- Medication History...
 - Prostaglandins
 - Bisphosphonates
 - Boniva/Actonel/Fosamax

© R. T. Cunningham, Jr et al.

TABLE 1. Drugs associated with uveitis^{a,b,c}

Allopurinol
Amphotericin B
Aspirin
Bismuth
Carbamazepine
Chlorbutolol
Clozapine
Colchicine
Cyclosporine
Diazepam
Diltiazem
Diphenhydramine
Ethambutol
Fluoxetine
Gold salts
Hydroxychloroquine
Hydroxyurea
Indinavir
Isoniazid
Levamisole
Lidocaine
Minocycline
Phenothiazines
Phenytoin
Propylthiouracil
Quinidine
Quinine
Risperidone
Sulfonamides
Tetracyclines
Valproic acid
Vincristine
Zalcitabine

^aSee accompanying list of drugs reported to be associated with uveitis.

^bSome drugs may be based on www.psychopharmacology.com.¹¹

^cFrom reference 11.

^dUveitis also associated with skin placement of purified protein derivative (PPD).

Guillen 2016; Eadie 2015

100

Traumatic Uveitis

- Classic findings:
 - Follows blunt trauma
 - Timing (2-7 days after injury)
 - Vision is typically good unless there is other damage to the eye
- Treatment:
 - Cycloplegia
 - Topical steroids
 - Look for other signs of ocular trauma in the eye (hyphema, iris tears, cataract, retinal problems)
 - Follow up 5-7 days

103

Masqueraders

- **Trauma** – intraocular FB
- **Tumors**
 - Lymphoma
 - Retinoblastoma
- **Endophthalmitis**
- **Retinal Detachment**

104

Ask the right systemic questions to help guide your differentials!

- Joint problems?
- Lower back pain?
- Pain on urination?
- Digestive problems?
 - Cramping, diarrhea, bloody stool?
- Lung/breathing problems?

- Rashes/skin problems?
- Any recent foreign travel?
- Been hiking/camping? Possible exposure to ticks?
- Any other systemic or autoimmune disease?

105

Laboratory Testing

106

When to test?

- Bilateral
- Recurrent
- Intermediate, posterior, or panuveitis
- Obvious systemic complaints
- Intense inflammation

107


Laboratory Testing

- Challenging
- Use history, ROS, knowledge of systemic diseases
- Practice evidence-based medicine
- Routine lab testing – yield is not that high
- Know your lab tests
 - Sensitivity
 - Specificity

108

If You Order Tests...

- Interpret
 - Get a good reference book!
 - Commercial lab websites (labcorp, quest)
- Communicate
- Treat
- Refer



109

Lab Testing in Anterior Uveitis

- Often Freebie if...
 - First occurrence
 - Acute
 - Mild
 - Unilateral
 - Nongranulomatous

110

No lab testing also...

- Evidence of HS, HZ
- Post-operative
- Trauma
- Known systemic disease
- Corresponds with new medication
- Remember – high % are idiopathic...

111

Suggested initial labs

- No universal recommended approach

• Anterior Uveitis

- HLA-B27
- ACE
- Lysozyme
- FTA-ABS
- RPR or VDRL

• Intermediate Uveitis

- ACE
- Lysozyme
- *Borrelia burgdorferi* IgG/IgM antibodies
- RPR/FTA-ABS


• Posterior Uveitis

- ACE
- Lysozyme
- ANA
- ANCA
- *Borrelia burgdorferi* IgG/IgM antibodies
- *Bartonella henselae* IgG/IgM antibodies
- FTA-ABS
- RPR
- *Toxoplasmosis gondii* IgG/IgM antibodies

112

HLA-B27

- HLA-B27
 - Up to 8% of general population
- Seronegative spondyloarthropathies
 - Ankylosing spondylitis
 - Reactive arthritis
 - IBD (ulcerative colitis; Crohn disease)
 - Psoriatic arthritis
- Normal: negative
 - Most useful information



113

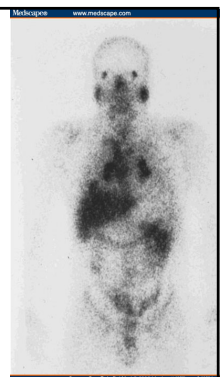ACE (Angiotensin Converting Enzyme)

- Helps confirm dx of sarcoidosis
 - ACE elevated in 60% of sarcoid patients
- Best for patients > 20 YO
- 12 hour fast before test
- Normal under 67 U/L
 - Over 100 U/L = highly suggestive
- Sensitivity and specificity only 60% and 70%

114

Sarcoidosis: Other Lab Tests

- Chest X-Ray / CT scan
- Liver enzymes
- Conjunctival or lacrimal gland biopsy
- Serum lysozyme
- Serum calcium
- Gallium scan – poor predictive value
 - Nuclear medicine test
 - Radioactive gallium citrate is injected
 - Hot spots at site of inflammation



115

Syphilis Testing

Treponemal-Based

- FTA-ABS (fluorescent treponemal antibody absorption)
- MHA-TP (microhemagglutination treponemal pallidum)

Nonspecific

- RPR (rapid plasma reagin)
- VDRL (venereal disease research laboratory)

116

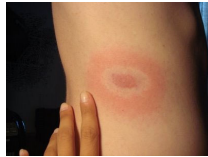Syphilis

RPR or VDRL	FTA-ABS or MHA-TP	Interpretation
+	+	Active Syphilis
-	+	Adequate Treatment (Inactive)
+	-	False positive
-	-	No exposure

117

Lyme Disease

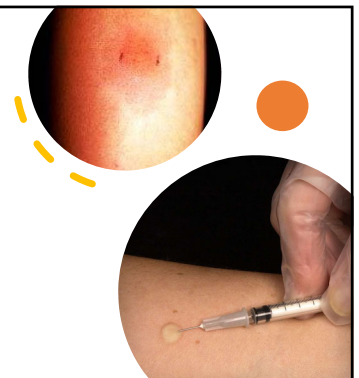
- Endemic?
- Exposed?
- *Borrelia burgdorferi* : IgG/IgM antibody titers (lyme)
- Western blot confirmation



118

TB Testing

- Depends...
- Prevalence?
- Previous exposure?
- Risk Factors
- PPD
- QuantiFERON Gold



119

Targeted laboratory testing

120

ANA (Antinuclear antibody)

- Evaluates immune system
- Screening test for SLE
 - 95%
- Sensitive but not specific
- Normal: nonreactive
- Results in 4-5 days
- SLE- 95 %
- Scleroderma- 60-90%
- Rheumatoid arthritis- 41%
- Sjogren's syndrome- 48%
- JIA with uveitis – 80% positive
 - 2/3 with oligoarticular JIA

121

p-ANCA

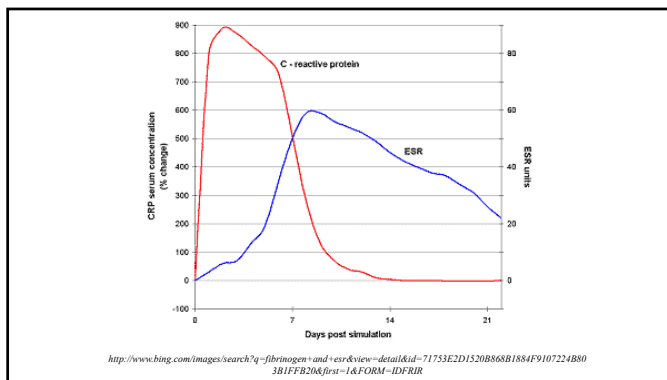
- Perinuclear-Antineutrophil cytoplasmic antibody
- ↑ in Crohn disease
- c-ANCA (antineutrophil cytoplasmic antibody C)
 - Autoimmune vasculitis
- Normal – titer <1:40

122

Non-specific tests

- CBC with differential
- Erythrocyte Sedimentation Rate (ESR)
 - M: $\text{age}/2$
 - F: $(\text{age}+10)/2$
- C-Reactive Protein

123



124

Other Diagnostic Procedures

- Radiologic Studies
 - Chest X-Ray / CT Scan
 - Sacroiliac joint
 - Other affected joints
- Anterior chamber tap

125

Keep in Mind...

- Most first episodes of acute, unilateral, nongranulomatous anterior uveitis are idiopathic
- Acute, **recurrent**, unilateral (may be alternating eyes) anterior uveitis... 50-80% are spondyloarthropathies
- Look closely for evidence of herpetic infection
- Think sarcoidosis if chronic granulomatous
- Have a suspicion about syphilis
- Refer as appropriate

126

Anterior Uveitis – Takeaway pearls

- Treatment often straightforward but may require persistence
 - Always overtreat rather than undertreat
 - Remember to hit it hard and taper slow
- DFE!
- Etiology not always so simple
 - Don't be afraid to order labs
- Look and listen for clues



127